A Vision Center of Excellence newsletter focused on ocular casualty care and readiness

FRONTLINES OF EYE CARE

SPRING 2017
ABRIDGED

IN THIS ISSUE

PERSPECTIVES FROM THE FRONTLINES

1 Lessons Relearned: An Army Ophthalmologist's Year at War

NOW SEE THIS

6 Vision Center of Excellence Focus on Emergency Ocular Care: Chemical Injuries

6 Emergency Management of Chemical Ocular Injuries: *For Non-Ophthalmic Providers*

7 Damage Control Ophthalmology: *For Ophthalmologists*

NEWS FROM VCE

8 Harvard Brings Focus to Blast Eye Injuries at the Military Vision Symposium on Ocular & Vision Injury

9 Recent and Upcoming Conferences, Presentations, and Publications

10 VCE Releases New Clinical Recommendation: Care of Oculomotor Dysfunction Associated with Traumatic Brain Injury

Managing Editor:
COL (Ret) Robert Mazzoli, MD, FACS

For questions or comments, email dha.bethesda.ncr-med.mbx.vision-center-of-excellence@mail.mil

Vision Center of Excellence
301-400-1130

vce.health.mil
facebook.com/VisionCoE
twitter.com/VisionCoE

Vietnamese patients treated by then LTC La Piana. (Source: COL La Piana)

PERSPECTIVES FROM THE FRONTLINES

LESSONS RELEARNED: AN ARMY OPHTHALMOLOGIST'S YEAR AT WAR

By: Francis G. La Piana, MD, FACS, COL (Ret) MC USA
Foreword by: Robert A. Mazzoli, MD, FACS, COL (Ret) MC USA

Though largely attributed to the more contemporary philosopher George Santayana, Edmund Burke said "Those who don't know history are doomed to repeat it." Given its universal and ageless truth, the saying could just as easily be attributed to Plato. Meanwhile, the military is often said to be guilty of precisely the opposite, of preparing to fight the last war. Kurt Vonnegut cynically retorted "We're doomed to repeat the past no matter what." Sadly, there is great truth in that as well. All in all, prudence dictates paying close attention to the past without being mired in it, in preparation for the future. Many refer to this as "lessons learned." Yet another truism is that such lessons, unless they result in change, are merely "lessons identified."

In this light, we have asked a number of military providers to share their insights into their experiences of combat eye care. The intent is to capture past lessons, both identified and learned, from this and prior conflicts in the hope that ocular combat casualty care is improved. Many of the contributors will share perspectives from combat deployment as clinicians. Others will reflect on their experiences deployed in administrative, non-clinical roles, far removed from their equipment and full clinical capabilities. Still others may provide insight into the day-to-day stateside impact of a war—a systems level perspective. An attempt was made to capture viewpoints from a number of perspectives: from active duty and reservists; from all services; from various theaters and various wars; and from various phases of combat, from expeditionary →

Disclaimer: Frontlines is a Vision Center of Excellence review of noteworthy findings from diverse fields within vision research. VCE receives operational support from the Navy within Department of Defense, and from the Office of Patient Care Services within the Department of Veterans Affairs. The views expressed in this publication are those of the authors and do not necessarily reflect the official policy or position of the Department of the Navy, Department of Defense, Department of Veterans Affairs, nor the U.S. Government. This work was prepared as part of official duties as U.S. Government employees and, therefore, is defined as U.S. Government work under Title 17 U.S.C.§101. Per Title 17 U.S.C.§105 copyright protection is not available for any work of the U.S. Government.

continued from page 1

to mature theater care, to stateside care. All accounts are intimate recollections. All are unfiltered and unvarnished. Save for asking "what would you change?" authors were provided minimal guidance on what to address; there was no template to follow and there was no attempt to constrain the topic. Consequently, the accounts will be deeply personal.

In this introductory reminiscence, Francis G. La Piana, MD, FACS, COL (Ret) MC USA, reflects on his experiences as a deployed ophthalmologist in Viet Nam. Dr. La Piana—a familiar and legendary name in Army and military ophthalmology as the primary champion for eye armor as we know it—successfully translated many of his experiences into true "lessons learned" after his return, most of which are enumerated in the indispensable Textbook of Military Medicine: Ophthalmic Care of the Combat Casualty and Emergency War Surgery texts. His long and storied career includes serving as an Army Special Forces Surgeon, Consultant to The Surgeon General of the Army, Professor of Surgery at USUHS, and as Chief of Ophthalmology, Walter Reed Army Medical Center. – R.A.M.

Have a story to tell or share?

Contact us at 301-400-1130

These lessons learned are shared here not because this author considers his experiences particularly unique, but because he considers it most important that lessons painfully acquired in war concerning the prevention and proper care of eye injuries must be recorded and shared with those who follow, and that it is remembered that, as Plotinus said, "knowledge without action is dead to us."

The 3rd Field Hospital, Tan Son Nhut, Vietnam, ca. 1970. *(Source: COL La Piana)*

In 1969, at the conclusion of my residency in ophthalmology at Walter Reed, I volunteered for duty in Vietnam. While having deployed twice to Africa as a Special Forces Officer, I had not served in Vietnam and felt that I should do so. My year-long tour of duty began in October 1969 and ended in October 1970. There was no pre-deployment training or instruction of any kind, but conversation with a recently returned ophthalmologist made me aware of equipment deficiencies and motivated me to purchase a set of microsurgical instruments, which proved most valuable. Upon arrival in Vietnam, I was sent to the 24th Evacuation Hospital to work with its ophthalmologist, then MAJ Dale Anderson, for a few weeks of orientation. Dale had been a senior resident when I began residency and again proved to be a kind and effective mentor. On the way to the operating room one day, we passed a soldier still in uniform breathing stertorously whose litter had been put to the side as he was "expectant" (i.e., expected to die from his head wound) as his distressed neurosurgeon told us. The thought of how much suffering was to be generated at home by his death struck me forcibly.

I was then permanently assigned to the 3rd Field Hospital in Ton Son Nhut which provided care for fresh casualties and outpatient care for a variety of patients. The staff was of generally high quality and complete except for the absence of a neurosurgeon, who would have completed the de facto head and neck team of an oral maxillofacial surgeon, a plastic surgeon, an otolaryngologist, and myself, an ophthalmologist. Outpatient eye care, per se was provided in the rear of an outpatient clinic where my office was next to the optometrist and the optician, both of whom were competent and hard-working individuals. My office was equipped with a slit-lamp and direct and indirect ophthalmoscopes, which permitted evaluations to be performed.

Stallard's Eye Surgery, 4th edition (1965), which had been recommended by my first chief at Walter Reed — Jack Passmore, a superb surgeon and gentleman who had served in Korea during the war there — proved of great and lasting value. Stallard had served in the British Army during World War II and I often felt

continued from page 2

that he was speaking to me directly as I tried to puzzle out some of the cases confronting me.

Other than for one week of R & R (rest and relaxation) with my wife in Hawaii, I was on duty full time and estimate that I took care of approximately 3500 patients: U.S. military and civilians, allied military (Vietnamese and Australian), and Vietnamese civilians (most of them indigent). I performed approximately 170 surgical procedures: globe repair, intraocular and periocular foreign body removal, enucleation with implant placement, ocular adnexal injury repair, orbital fracture repair, glaucoma and corneal procedures, strabismus correction, lacrimal drainage system procedures, orbital tumor resection, and trachoma-induced entropion correction. The almost total lack of follow-up was a major problem, as it appears to continue to be in our current wars. An important lesson I learned was that it was necessary to adhere to two different standards of practice, depending on the patient's circumstances. One standard applied to patients who could receive follow-up care in their home countries – for them, one deferred the performance of complex reconstructive procedures to more capable hands in their home countries. The other standard of care applied to indigent native patients who had no other access to care. For them, one felt obligated to do all that one could.

Because of the high incidence of polytrauma, it was very often necessary for me to operate while other surgeons were attending to injuries elsewhere. When I did not have eye or ocular adnexal injuries to deal with, I could be asked to first assist a general surgeon in such cases as extremity wound debridement. These experiences solidified my conviction that military ophthalmologists should see themselves as surgeons and learn as much as possible about other surgical disciplines, especially neurosurgery, oral maxillofacial surgery, and otolaryngology, by trying to spend time on these services during a surgical PGY-1 year and taking every opportunity to operate in conjunction with these surgeons. One's horizons are thereby expanded and one becomes a better surgeon overall. Our chief of professional services, Pete Peterson, was a plastic surgeon with whom I often operated. He not only taught me a lot but stimulated my desire to obtain more training in oculoplastic surgery.

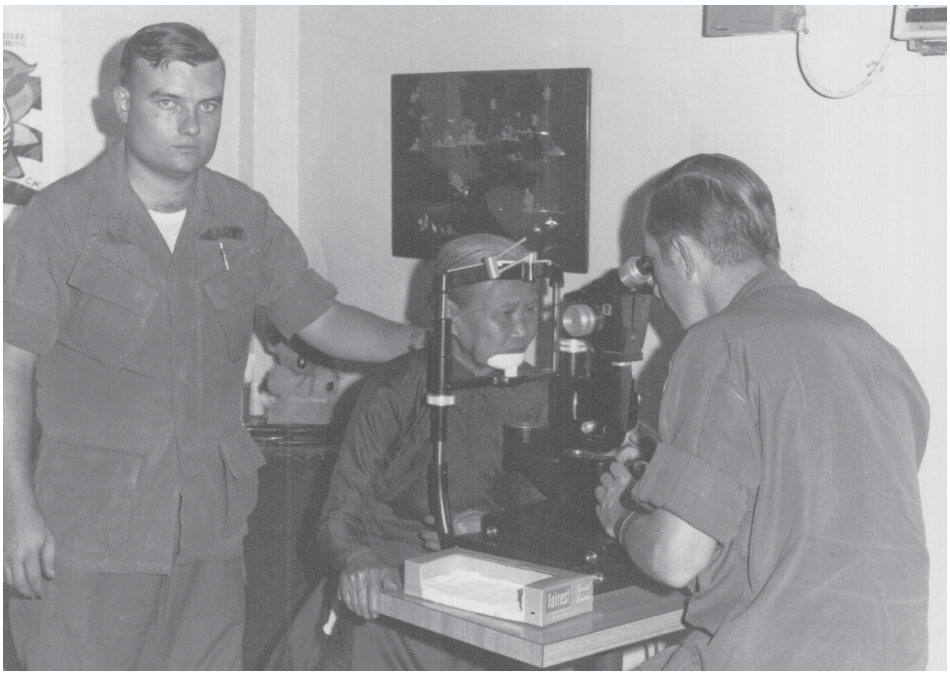

Slit-lamp examination on Vietnamese cataract patient brought to 3rd Field Hospital by Medical Civic Action Program (MEDCAP) soldier. (Source: COL La Piana)

We 3rd Field surgeons were called upon to treat both allied and enemy wounded. The Australians had their hospital in the south of Vietnam, but no ophthalmologist was on staff, so on one occasion I loaded surgical equipment on a helicopter and flew over the delta to provide care for an Aussie who was non-transportable. I had gone to school with Aussies in Japan and always enjoyed their company as they share many character traits with us.

We also operated with Vietnamese Army surgeons at Cong Hoa Hospital where I gave lectures to their ophthalmologists. Once, a Viet Cong terrorist, who had been caught in a bomb blast and had extensive general injuries in addition to severe eye injuries, was brought to the 3rd Field operating room but died on the table before we could help him. A major source of satisfaction for us was being encouraged and permitted to provide care for indigent Vietnamese civilians. Some – mostly farmers – were brought by Mennonite missionaries to my hospital where I performed cataract surgery on the majority, as well as a variety of other procedures including those for strabismus and trachoma on others. Dr. Anderson and I would travel to Ho Nai Hospital which was overseen by Brother Bernard, a French Canadian monk nurse, to perform cataract surgery. In addition, our own Medical Civic Action Program (MEDCAP) personnel brought their patients to us, most of whom needed cataract surgery. Dr. John Hodgkinson, an American Medical Association (AMA) ophthalmologist volunteer, and I provided instruction to Vietnamese ophthalmology residents, introducing them to the indirect ophthalmoscope.

Flexibility and creativity were essential. My hospital had no radiographic techniques for the localization of intraorbital foreign bodies, so I further modified the modified spectacle frame of Spindell to

continued from page 3

permit me to at least make a determination as to whether or not the foreign body was intraocular. At that time, giant magnet extraction was employed as soon as possible after injury and I was able to extract magnetic intraocular foreign bodies using it. I had learned to do intracapsular cataract surgery employing alpha chymotrypsin to release the zonules and a cryoprobe to extract the lens. Both of these being in very short supply, I taught myself to break zonules with a muscle hook and slide the lens out with capsule forceps with the help of Stallard's textbook. Inadequate equipment and limited supplies constituted significant problems. There were no operating microscopes available, so all eye surgery had to be performed under loupe magnification. Furthermore, there was often a lack of trained operating room assistants which made surgery more challenging.

Little interaction with other ophthalmologists created a sense of isolation at times. Nowhere in Vietnam was safe as the Viet Cong were ubiquitous. Though there was an arms room at the hospital, we were not issued personal weapons. With the memory of the Tet Offensive still fresh, we took the M-16 rifles left in the triage areas by casualties, and put them in our rooms. Since I frequently went elsewhere and could not openly carry a rifle, I had my father mail me a pistol (hidden in the bottom of a box of cookies sent by my mother) which I carried and, happily, never had to use. While sitting at my desk one evening studying for the American Board of Ophthalmology examinations, plaster showered down on my head as the result of a bomb detonated at the hospital's perimeter, which thankfully produced no casualties.

On night patrol while in Special Forces, the soldier in front of me had to be evacuated after being struck in the eye by a tree branch – my own eyes being protected by glasses. This led to the thought that it was mindless that some form of eye protection wasn't provided to Infantrymen. I tested a primitive form of such eye protection on the 1st Air Calvary Division in Vietnam and was further stimulated to continue efforts to facilitate the development of definitive eye protection by the eye causalities I cared for. Especially one soldier who, while I was examining his severely damaged eyes, said "it's awfully dark doc." I promised myself then that I would do all I could during the remainder of my time on active duty to facilitate the development of eye protection. After 25 years of effort by many within and outside the Department of Defense, the objective has been partially realized in that small fragment injuries are usually prevented by devices on the Army Protective Eyewear List (APEL), but the threat from blast injury has not yet been countered.

Cataract surgery at Ho Nai Hospital. *(Source: COL La Piana)*

Perhaps all wars are surreal, but the war in Vietnam certainly was for me. Having traveled to Cam Ranh Bay in the course of armor development, I spent an evening with my hosts eating a steak, drinking good whiskey, and watching live harassment and interdiction artillery fire from across the valley. Added to the stress engendered by absence from my wife and three young children were the generally negative feelings about the conduct and very existence of the war. Though these feelings came to be shared by everyone I worked with, all did their work well.

Shortly before I came home, two Vietnamese Army ophthalmologists took me to dinner. One had come down from the north, the other was from the south. After a few glasses of wine, I asked them what they thought would happen when the Americans left. The one from the north said "we will hold them" (the North Vietnamese Army); the one from the south smiled sadly and said, "when the Americans leave, the north will come down and sweep everything before it," which tragically is what happened. Upon returning home, I was asked to prepare a history of Army ophthalmology in the Vietnam war. I reviewed the reports made by Army ophthalmologists who had served in the prior wars of the 20th century and realized that the problems they encountered and the solutions they suggested were identical to my own:

1. There is no delayed primary closure in ophthalmic surgery.
2. The first surgical procedure peformed on the injured eye and/or its adnexal structures is almost always the critically important one and must be performed as soon after injury as possible.
3. We therefore must be prepared to practice such definitive expert surgery in the combat zone and to do so requires the presence of subspecialty trained ophthalmologists in certain of its hospitals serving as members of a head and neck team comprised of neurosurgeons, otolaryngologists/maxillofacial surgeons and others as necessary. They must be supported by appropriate equipment, including computerized tomography (CT) scanners and operating microscopes, and trained nurses and corpsmen.

continued from page 4

4. A senior (O-6/COL) ophthalmologist – preferably one who has served in a previous war – must function as the theater ophthalmologist supervising and coordinating all aspects of eye care in the combat zone (CZ) and the appropriate allocation and utilization of all resources – both personnel and material.
5. A registry of eye injuries and disease must be established and maintained from the onset of hostilities.
6. Eye protection must be worn during the conduct of all potentially eye hazardous activities on and off duty.
7. Ophthalmologists in theater must be cognizant of the type of eye care available to casualties during air evacuation from the CZ, as this determines to a significant degree the timing of such evacuation.

What can be said about the differences between then (45 years ago) and now (the Gulf Wars)?

There have been significant improvements in our ability to prevent and treat eye injuries in war: eye protection made part of the uniform; operating microscopes and CT scans in theater; establishment of the head and neck teams; deployment of subspecialists; establishment of a senior theater ophthalmology consultant (Col [Ret] Tom Mader in Desert Shield/Storm); general improvements in eye surgical techniques and equipment; much improved registries of eye injuries; the establishment of the Ocular Trauma Lab, the tri-service Ocular Trauma Course, and the Vision Center of Excellence; especially the ongoing efforts of COL (Ret) Robert Mazzoli to enhance all aspects of eye care of Service Members, an example being the substitution of shielding for protecting the injured eye instead of patching it. Some old problems persist and new problems have developed. The care of eye casualties during aeromedical evacuation from the combat zone remains limited and the increased employment of improvised explosive devices (IEDs) by the enemy has produced an increased incidence of blast injury to the eye and associated structures that are not countered by currently available forms of eye protection.

As Plato (perhaps) observed, and Santayana certainly did, "only the dead have seen the end of war." Today's newspapers tragically confirm this observation. Enemies will continue to develop new weapons for which countermeasures must be developed, therefore the ongoing improvement in eye protective devices must continue. Ophthalmology will continue to make advances in the treatment of ocular and ocular adnexal injuries and diseases. Such advances must be incorporated into military ophthalmology as soon as possible, for no one deserves the best available eye care more than those who "stand in the day of battle" for us all. Military ophthalmologists must continue to learn about eye care in war because it is qualitatively different from the provision of such care in peace. Some military ophthalmologists of the three uniformed services must acquire such experience so as to know how to advise upon and lead training and readiness for eye care in future wars. To fail in any of these objectives is to condemn our Service men and women to preventable blindness.

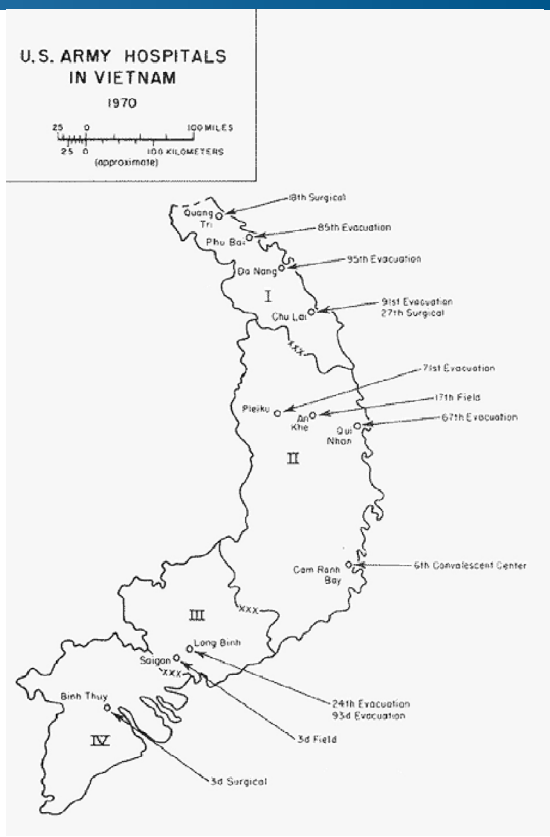

Map of U.S. Army Hospitals in Vietnam, 1970. (Source: COL La Piana)

Triage area, 3rd Field Hospital. (Source: COL La Piana)

NOW SEE THIS TRAUMA & DAMAGE CONTROL OPHTHALMOLOGY

VISION CENTER OF EXCELLENCE

NOW SEE THIS

VISION CENTER OF EXCELLENCE FOCUS ON EMERGENCY OCULAR CARE: CHEMICAL INJURIES

Emergency management of ocular trauma and damage control ophthalmology (DCO) are necessary for both the ophthalmic and non-ophthalmic communities. To this end, VCE is sharing quarterly emergency management tips for the ophthalmic and non-ophthalmic communities as well as damage control ophthalmology principles specifically for the ophthalmologist.

Damage control principles for combat casualty care have been defined for interventional life and death and acute resuscitative procedures (i.e., Damage Control Surgery and Damage Control Resuscitation), and are integrated into military medical practice through clinical practice guidelines, surgical guidelines, and training courses. However, no similar principles and practice guidelines exist for the ophthalmologists in the initial management of combat-related ocular injuries.

In this issue of Frontlines, we share established principles for treatment of chemical ocular injuries.

A wide variety of chemical substances are known to cause serious and vision-threatening eye injuries when they come into contact with the eye. Solid and liquid forms of cleaning products, bleaches, and acids are the most common substances associated with ocular injuries and have led to an increase in daily injuries, particularly in children. In the military, detergents and descalers for ships and aircraft are common and can also cause chemical injury. Less commonly reported substances include the accidental use of super glue, ear medication, and ointments not for use in the eye.

Further principles regarding combat-related ocular trauma need to be developed and formalized. VCE is currently developing DCO principles, which will encompass the following: necessity, urgency, adequacy, and avoidance.

Irrigation of the eye using saline and a lid speculum. (Source: James W. Karesh, MD)

Emergency Management of Chemical Ocular Injuries: For Non-Ophthalmic Providers

PRINCIPLE 1: It is necessary to copiously and thoroughly irrigate an eye injured by exposure to chemicals. Urgent and immediate irrigation aids in reducing damage to the eye. As the saying goes: "Dilution is the solution"

- Immediately irrigate the eyes for at least 30-60 minutes (approx. 20 liters or more of fluid) to remove all traces of any hazardous chemical
- Chemicals absorbed by the cornea are more difficult to dilute and neutralize which is the reason there can be no delay in instituting ocular irrigation following a chemical injury
- Use any means to irrigate the eye: pouring water from a container, using a patient's hydration pack in combat, or immersion of the head into a container. A continuous eye irrigation system can be constructed by attaching a saline bag to IV tubing, which then attaches to a nasal cannula
- White phosphorus is a particularly damaging chemical sometimes present in combat. Place saline- or water-soaked dressing on all white phosphorus particles (identified by flame/smoke) and evacuate immediately to the nearest military treatment facility with an available ophthalmologist

continued from page 6

A continuous eye irrigation system can be constructed using a nasal cannula. (Source: James W. Karesh, MD)

PRINCIPLE 2: Direct exposure and visualization of the cornea and conjunctiva are necessary for effective and successful irrigation and removal of all traces of any chemicals injurious to the eye

- It is important to separate the eyelids when irrigating the eye; significant pain is associated with chemical injuries to the eye and separating the eyelids during irrigation may require assistance. One or two drops of a topical ocular anesthetic (proparacaine ophthalmic or tetracaine ophthalmic drops) are also helpful for pain control during irrigation
- If the chemical includes particulate matter, the upper and/or lower lids must be flipped over to remove any particles adherent to the conjunctival surface of the eyelid; a cotton-tipped applicator can be used to facilitate eyelid eversion

Damage Control Ophthalmology: For Ophthalmologists

DCO PRINCIPLE 1: Removal of all remnants of the offending chemical is necessary for reducing damage to the cornea and preserving vision. "Dilution is the solution" is the mantra for managing chemical injury

- Perform an adequate irrigation; you cannot over-irrigate a chemical injury
- Irrigation must start within minutes of injury to mitigate the extent of damage and loss of vision
- Evert the eyelids to check for residual debris and foreign material; remove this material
- Checking the pH of the tear film may be helpful in determining the presence of residual material and the need for further irrigation
- If treating white phosphorus burns, avoid contact with and remove all white phosphorus particles surgically under water. If immersion of affected tissue is not possible, employ continuous irrigation to cut off oxygen supply to particles. Follow up with standard burn care

DCO PRINCIPLE 2: Rapid healing of damaged corneal and conjunctival epithelium is necessary to prevent sight-threatening scarring of the conjunctiva and cornea. Healing of damaged corneal and conjunctival epithelium can be facilitated by a variety of adjunctive medications and treatment

- Appropriate ophthalmic antibiotic drops to prevent infection
- Topical ophthalmic steroid drops to reduce inflammation
- Cycloplegic drops to reduce ciliary spasm and pain
- Vitamin C orally (2g orally daily) promotes collagen remodeling; can also be formulated as a 10% ophthalmic drop (hourly for 72 hrs, then 4 times a day)
- Twenty percent acetylcysteine formulated as an ophthalmic drop is a collagenase inhibitor (hourly for 72 hrs, then 4 times a day)
- Ten percent sodium citrate formulated as an ophthalmic drop is a collagenase inhibitor (hourly for 72 hrs, then 4 times a day)
- Gentle debridement of loose or necrotic corneal epithelium under slit-lamp magnification is helpful for promoting corneal healing
- If available, early placement of an amniotic membrane graft is useful in severe chemical injuries

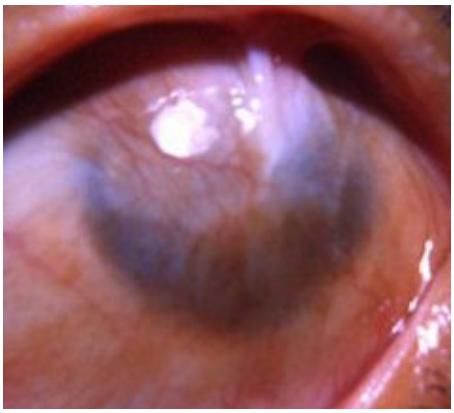

Scarring with marked neovascularization of the cornea due to alkali chemical injury. (Source: EyeRounds, The University of Iowa)

continued from page 7

NEWS FROM VCE: HARVARD BRINGS FOCUS TO BLAST EYE INJURIES AT THE MILITARY VISION SYMPOSIUM ON OCULAR & VISION INJURY

DoD and VA presenters at the 6th Military Vision Symposium on Ocular & Vision Injury hosted by Schepens Eye Research Institute and Harvard Medical School included (standing, from left) LTC Marcus H. Colyer, MD, MC USA (DoD Walter Reed National Military Medical Center [WRNMMC]), Mr David Ritzel (DoD Dyn-FX Consulting), COL (R) Robert A. Mazzoli, MD FACS (DoD-VA VCE), Col (R) Glenn C. Cockerham, MD (Veterans Health Administration [VHA]). (Source: James W. Karesh, MD)

Publications and Conference Presentations

The following publications and presentations highlight contributions from VCE staff and collaborators.

Recent Presentations

6th Military Vision Symposium on Ocular & Vision Injury, Schepens Eye Research Institute, Harvard Medical School

30-31 March 2017, Boston, MA

Sponsored by the Schepens Eye Research Institute, Massachusetts Eye and Ear Infirmary, and Harvard Medical School Department of Ophthalmology, the 6th Military Vision Symposium on Ocular & Vision Injury was a collaborative symposium for vision researchers, ophthalmologists, and military subject matter experts to explore the latest advancements in eye research and military vision care, this year focusing on blast eye injuries. The incidence of blast-related combat ocular injuries has steadily increased with the evolution of weaponry involving high-energy explosive devices and advanced tactics and technologies. These explosive devices cause injury to areas that are not always well-protected by body armor, such as the eyes. This event focused on combat ocular trauma — one of the most common, yet overlooked types of war injuries. During this meeting, experts in the field of blast-related ocular trauma held panel discussions and gave lectures and presentations in the areas of blast physics, consequences of blast eye injury, and the rehabilitation and restoration of blast injuries. Public health aspects of eye injuries in mass casualty incidents were also a focus. In particular, the medical response at the Boston Marathon bombing was discussed, as well as the importance of data collection and the development of preparedness programs for mass casualty incidents such as bombings and natural disasters.

- Website Link: http://eye.hms.harvard.edu/military

Conference Presentations

Public Health Aspects of Eye Injuries in Mass Casualty Incidents

Robert A. Mazzoli, MD, FACS, COL (Ret) MC USA
DoD-VA VCE

Overview of Blast Eye Injuries

Robert A. Mazzoli, MD, FACS, COL (Ret) MC USA
DoD-VA VCE

Open Globe Injuries

LTC Marcus H. Colyer, MD, MC USA
DoD WRNMMC

Visual and Ocular Consequences of Blast

Glenn C. Cockerham, MD, Col (Ret) MC USAF
VHA

continued from page 8

National Capital Area TBI Research Symposium 2017, National Institutes of Health
8-9 March 2017, Bethesda, MD

Poster Presentation

Visual Neurosensory Effects Associated with Military Concussion/TBI

Felix M. Barker, II, OD, MS, FAAO, *(DoD-VA VCE)*; Natalya Merezhinskaya, PhD *(DoD-VA VCE)*

2017 Research and Innovation Month, Walter Reed National Military Medical Center
1-5 May 2017, Bethesda, MD

Poster Presentations

Clinical Outcomes of Open Globe Injuries in the Defense and Veterans Eye Injury and Vision Registry (DVEIVR)

David A. Eliason, MD; Aliona Gherman, MD; Helen A. White; Tom Velez, PhD; Jerry Flanagan, OD, PMH; Timothy Tschampel; James Hagerty; Haymanot Berhe; Keith Leatherwood; Ariel Fernandez; Adam Rivera, Sammi York

Evidenced Based Vision Data to Improve Vision Health, Support Military Readiness,Enhance Education, and Inform Policy

Helen A. White; Aliona Gherman, MD; David A. Eliason, MD, Tom Velez, PhD; Jerry Flanagan, OD, PMH; Timothy Tschampel; James Hagerty; Meika Ungricht; Haymanot Berhe; Milo Shank; James B. Howells; Sammi York

Extrusion of a Metallic Intraocular Foreign Body Following MRI

Jason R. Lewis, DO; James W. Karesh, MD; Keith J. Wroblewski, MD, Eva Chou, MD

The Ocular Manifestations of Mosquito Transmitted Diseases

James Karesh, MD, FACS and Robert A. Mazzoli, MD, FACS

Development of a Pathway for Advanced Compositional Analysis of Periocular, Orbital, and Intraocular Foreign Bodies

Robert A. Mazzoli, MD FACS; James W. Karesh, MD FACS; Michael R. Lewin-Smith, MD; Natalya Merezhinskaya, PhD; Paul A. Latkany, MD; Jo Ann Egan, BSN, MS; Eva Chou, MD; Michael J. Mines, MD; Erin S. Seefeldt, MD; Marcus H. Colyer, MD; Frank La Piana, MD

Rehabilitation of Patients with Visual Field Loss Associated with Traumatic or Acquired Brain Injury

Felix Barker II, OD, MS, FAAO; Paul Koons, MS; John Kingston, MA; Glenn Cockerham, MD; Natalya Merezhinskaya, PhD; William Boules, MS

The Association for Research in Vision and Ophthalmology (ARVO) Pre-Meeting: Special Session on Eye & Vision Trauma
7 May 2017, Baltimore, MD

Invited Lecture

Advances in Military Ocular and Combat Casualty Care: Translating Lessons Learned In War To Peacetime Practice

Robert A. Mazzoli, MD, FACS, COL (Ret) MC USA

Open Globe Injuries in the Defense and Veterans Eye Injury and Vison Registry (DVEIVR)

David Eliason, MD

continued from page 10

Recent Publications

McLaughlin A, Colyer MH, Ryan DS, Sia RK, Weichel ED, Spiegelman A, Eaddy SG, Mazzoli RA, Bower KS. Self-Reported Visual Quality of Life After Combat Ocular Trauma. *Military Medicine.* 2017;182(S1):239-242.

Vlasov A, Ryan DS, Ludlow S, Coggin A, Weichel ED, Stutzman RD, Bower KS, Colyer MH. Corneal and Corneoscleral Injury in Combat Ocular Trauma from Operations Iraqi Freedom and Enduring Freedom. *Military Medicine*. 2017;182(S1):114-119.

Lynch MG, Maa A, Delaune W, Chasan J, Cockerham GC. Eye Care Productivity and Access in the Veterans Affairs Health Care System. *Military Medicine*. 2017;182(1):e1631-e1635.

Lattimore MR. Human Contrast Acuity Variability. *Military Medicine*. 2017;182(S1):234-238.

Williams ST, Harding TH, Statz JK, Martin JS. Blast Wave Dynamics at the Cornea as a Function of Eye Protection Form and Fit. *Military Medicine*. 2017;182(S1):226-229.

Upcoming Presentations

American Society of Ophthalmic Plastic & Reconstructive Surgery (ASOPRS) 2017 Spring Scientific Symposium

22-25 June 2017, Vancouver, CA

Invited Lecture

Advances in Military Ocular and Combat Casualty Care: Translating Lessons Learned In War To Peacetime Practice

Robert A. Mazzoli, MD, FACS, COL (Ret) MC USA

VCE Releases New Clinical Recommendation: Care of Oculomotor Dysfunction Associated with Traumatic Brain Injury

The Vision Center of Excellence (VCE), in collaboration with an expert workgroup panel of DoD, VA, and civilian and academic ophthalmic and optometric specialties, has developed the clinical recommendation (CR): Care of Oculomotor Dysfunctions Associated with Traumatic Brain Injury. This CR is designed to help guide eye care providers through the assessment, management, and rehabilitation of patients with oculomotor dysfunction associated with TBI. Included in this CR are clinical tests that can evaluate and identify the most common TBI-related oculomotor dysfunctions, as well as rehabilitation procedures and guidance for treatment options.

- Website Link: http://vce.health.mil



FRONTLINES OF EYE CARE

Published by Vision Center of Excellence **vce.health.mil**

facebook.com/VisionCoE twitter.com/VisionCoE